

Open Book

Learning from close calls and adverse events

Hypoxic cardiac arrest during attempted percutaneous tracheostomy

This report alerts providers of the risk of hypoxic cardiac arrest during percutaneous tracheostomy. The aim is to learn from the event and establish a standard operating procedure to prevent future similar events.

This report is relevant to those working in operating theatres, perioperative areas and radiology departments. Please consider the report and whether the suggested changes are relevant to your own systems.

Chronology

- A patient required venovenous extracorporeal membrane oxygenation (VV ECMO), renal replacement therapy and prolonged vasoactive support for postoperative severe multiorgan failure.
- By postoperative day 10 the patient was stable enough to be weaned from VV ECMO.
- On postoperative day 11 a percutaneous tracheostomy (PT) was attempted that resulted in a major vascular injury and a hypoxic cardiac arrest secondary to blood clots in the airway. The patient was emergently transferred to an operating room where the profound hypoxia was eventually resolved by repeated suctioning of blood clots from the airway.
- An injury to a 'high-riding' innominate artery was identified, but this needed no intervention as by the time it was identified the bleeding had ceased. A surgical tracheostomy was placed. The patient subsequently died from non-occlusive mesenteric ischaemia some 36 hours after the injury.

Investigation

The increased risk of a PT was not recognised in this patient. A non-contrast CT of the chest had been performed months before the procedure as part of the work up for lung transplantation and this demonstrated the high-riding innominate artery (see Diagrams 1 and 2). However, this abnormality was not mentioned in the report as the focus of the examination was the lungs. This vascular abnormality is present in approximately 0.3 percent of patients.¹

1 Netzer A, Ostrovsky D, Bar R, et al. 2010. Protection of high-riding aberrant innominate artery during open tracheotomy. *Journal of Laryngology and Otology* 124(8): 892–5. URL: <https://doi.org/10.1017/S0022215110000836>.

Diagram 1: The normal position of the innominate artery relative to the trachea.

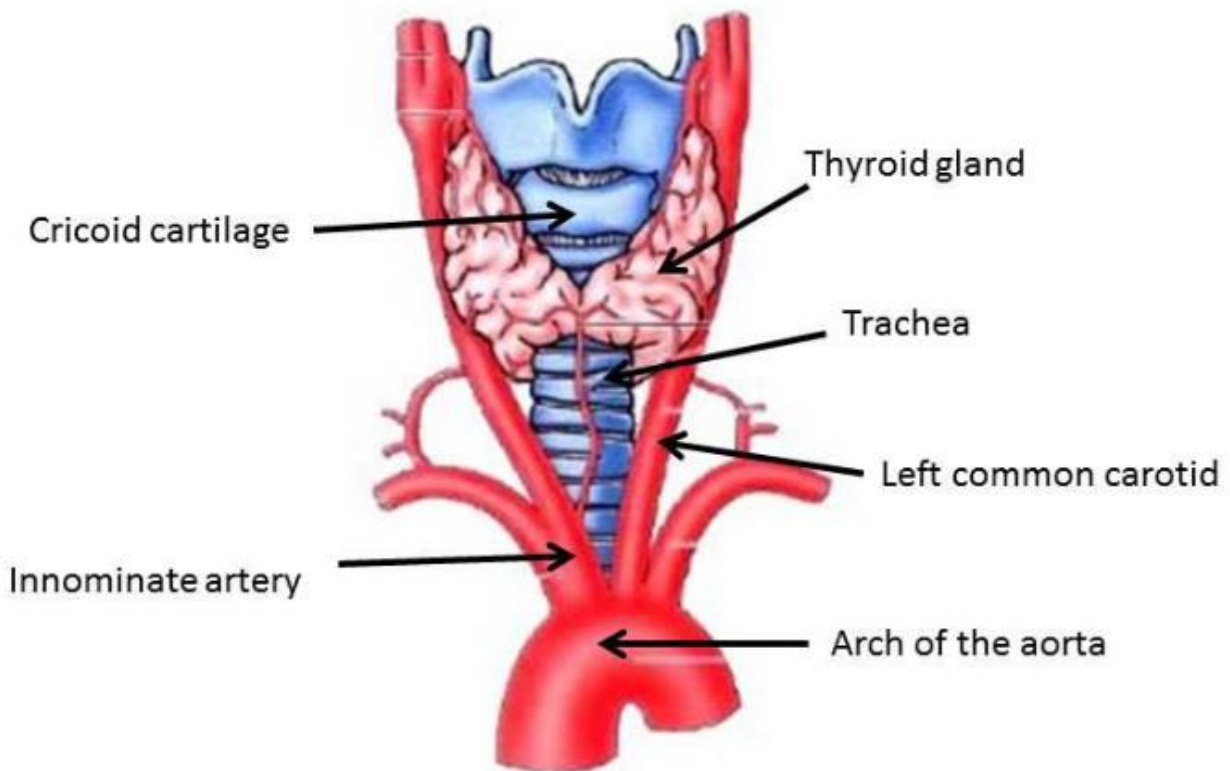
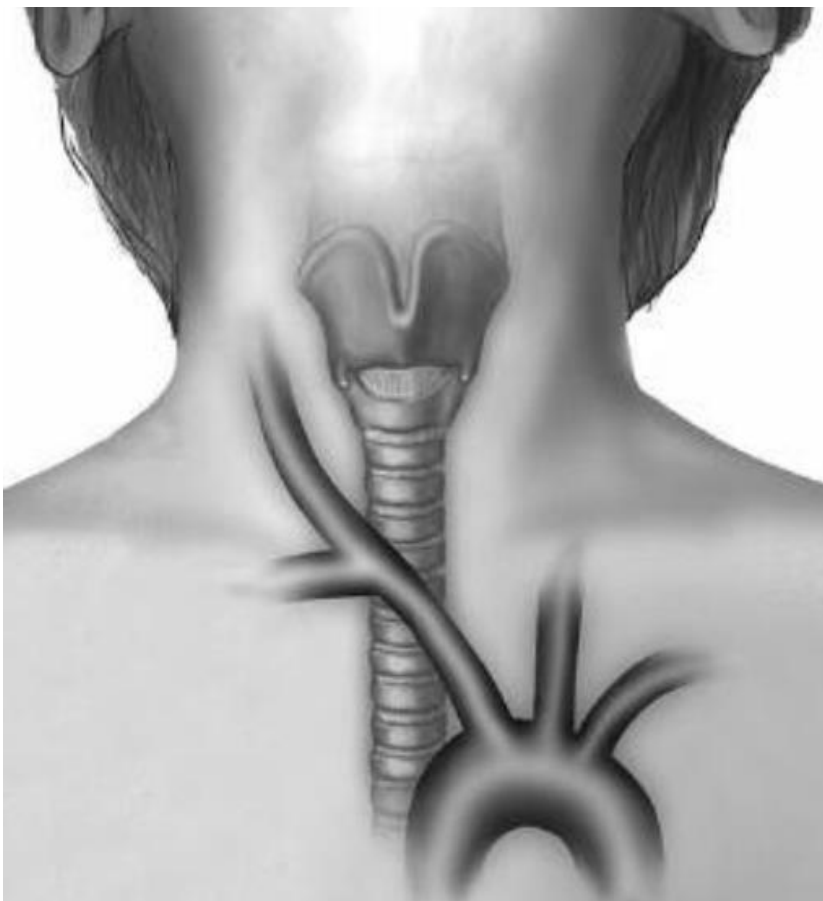


Diagram 2: Abnormal position of the innominate artery relative to the trachea. The artery starts on the left of midline and crosses the trachea in the lower neck.



A surgical ‘time out’ was not routinely performed prior to a PT being undertaken at the bedside in the intensive care unit. A deliberate ‘pause point’ where relevant radiology is looked for and reviewed may have allowed the team embarking on the procedure to identify this risk and mitigate it.

Subsequently, the needle insertion into the trachea was too low and this was not identified. Needle insertion was not straightforward and several passes were needed.

While agreed standards were met – a physical examination of the front of the neck was performed – the low entry into the trachea was not identified at bronchoscopy prior to dilation. It was unclear whose responsibility (the operator or the bronchoscopist) it was to identify the level at which the needle had entered the trachea. At operation the entry point was documented to be between the 6th and 7th tracheal rings. This low position was not appreciated by the operator prior to dilatation of the tract and may have been because inadvertent, gradual migration of the bronchoscope into the trachea occurred while difficulty was encountered placing the needle into the trachea.

Actions

To develop a standard operating procedure for PT to provide clarity as to what is currently believed to be the best practice for performing this procedure.

This standard operating procedure should include the need for the team to both perform a ‘time out’ and consider whether there is any relevant imaging that should be reviewed prior to starting the procedure.

Consideration should also be given to stating explicitly in the standard operating procedure which clinician is responsible for determining at what level the needle has entered the trachea.